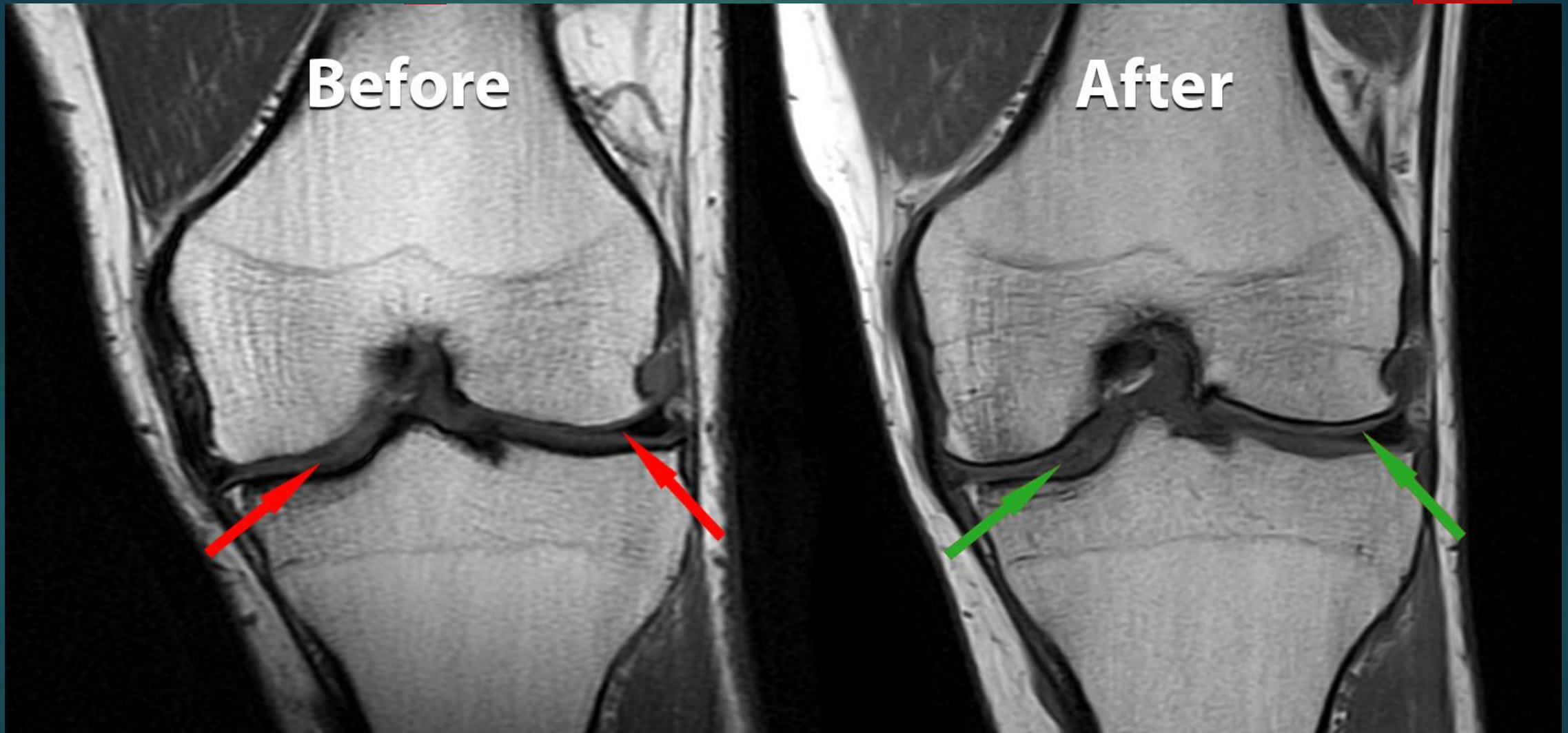


2nd Documented Case of Cartilage Regeneration

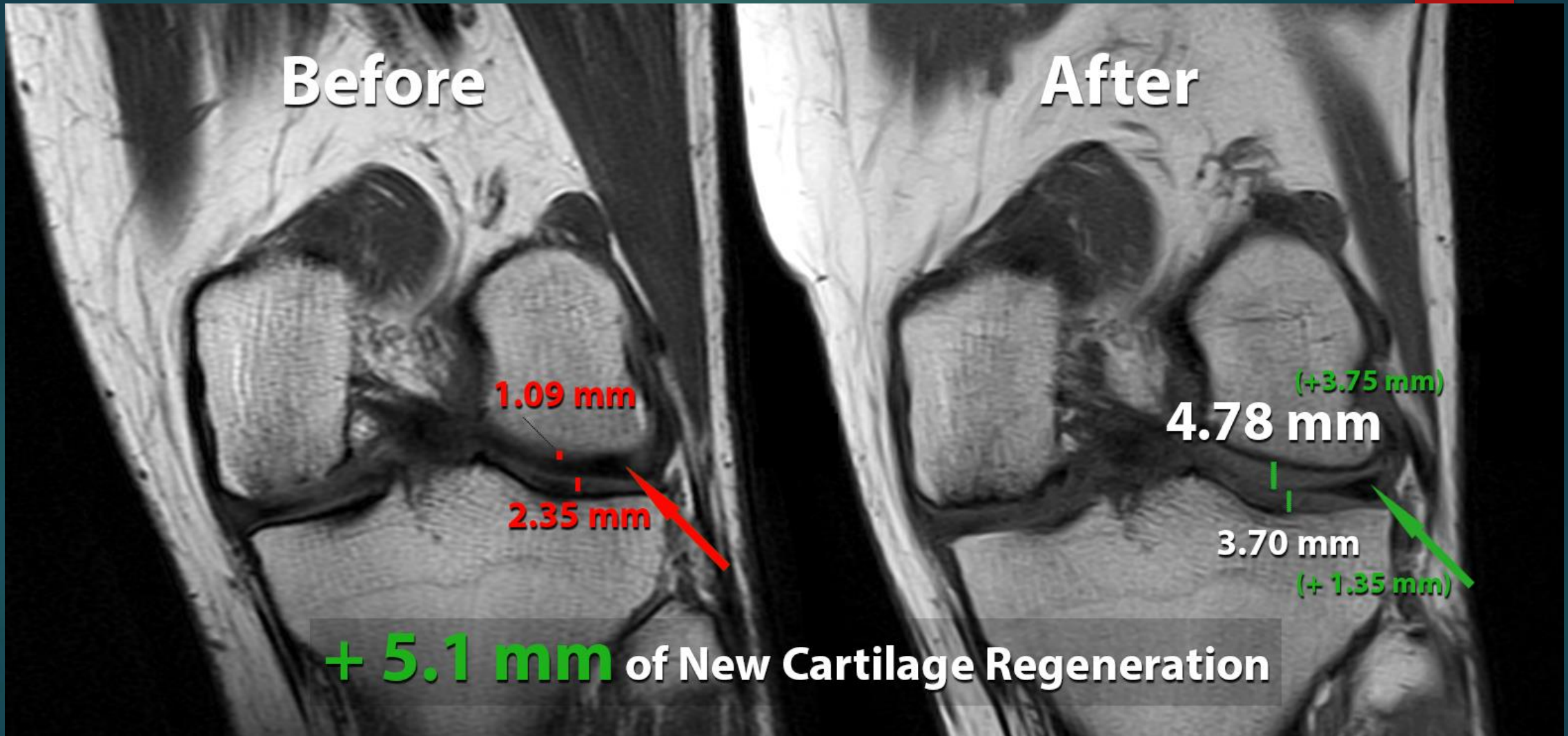


MRI FINDINGS - 12/14/2016 compared to 1/08/2018:

- **“Findings indicate increasing thickness of the articular cartilage in the femoral , tibial and patellar articular surfaces.”**

Thomas Fabian, M.D. Board Certified Radiologist

2nd Documented Case of Cartilage Regeneration



MRI FINDINGS - 12/14/2016 compared to 1/08/2018:

- “Findings indicate increasing thickness of the articular cartilage in the femoral , tibial and patellar articular surfaces.”

Thomas Fabian, M.D. Board Certified Radiologist